

Immune Phenomena in Glaucoma and Conformational Disorders: Why is the Second Eye Not Involved?

Markus H. Kuehn, PhD

Abstract: Data along several lines of evidence have suggested that a systemic autoimmune response may be provoked in glaucoma and could contribute to retinal ganglion cell loss. If such an autoimmune response exists, one could predict that in cases of unilateral glaucoma, autoantibodies generated would affect both eyes, leading to damage in the unaffected, contralateral eye in an intraocular pressure-independent manner. However, such an effect has not yet been reported. There are currently no data to reconcile these contrasting observations but a review of the literature suggests a possible explanation.

Key Words: exfoliation syndrome, parainflammation, innate immunity, autoimmunity

(*J Glaucoma* 2014;23:S59–S61)

THE CONTRALATERAL EYE IS FREQUENTLY NOT NORMAL IN EXPERIMENTAL GLAUCOMA MODELS

Elevated intraocular pressure (IOP) reliably leads to the progressive retinal ganglion cell (RGC) loss and optic nerve axonal damage in mice, rats, and monkeys. A number of experimental approaches are available to induce elevated IOP in 1 eye of these animals, including laser coagulation of the episcleral veins, injection of microbeads or hyaluronan into the anterior chamber, or episcleral vein injection of hypertonic saline.^{1–5}

One of the perceived benefits of inducible models was that glaucoma could be induced in 1 eye, the contralateral eye serving as an internal control. However, observations suggest that the contralateral eye is not normal in these animals and exhibits clear differences from eyes obtained from naive animals. For example, Gallego et al⁶ found elevated levels of glial fibrillary acid protein (GFAP), major histocompatibility complex class II molecule (MHC-II), and neurofilament of 200 kD (NF200)-positive RGC in the control eyes of mice with unilaterally elevated IOP, indicating macroglial and microglial activation and RGC damage. There was a mild progressive RGC loss in the uninduced eyes in a model of ischemia/reperfusion damage.⁷ As a consequence, many investigators have now moved away from using the contralateral eye as a normal control, relying on eyes from naive animals instead.

How, then, could a neurodegenerative stimulus be transmitted to the unaffected eye in induced animal models? One mechanism might be through cytokines secreted into

the circulation by the affected eye, but to date little data exist to support the notion of elevated serum levels of proinflammatory cytokines and it is difficult to imagine that the retina would synthesize sufficiently large quantities of such compounds to raise steady-state levels systemically. Alternatively, it is also possible that degenerative impulses are transmitted to the contralateral eye through the visual centers of the brain. There is good evidence of degenerative changes in the lateral geniculate nucleus in primates with elevated IOP and in human glaucoma patients.^{8–10} It is conceivable that this process also affects the synaptic terminals of RGC in the unaffected eye that extend ipsilateral projections to the same lateral geniculate nucleus. However, there are currently no data to either support or discount this possibility.

SERUM ANTIBODIES AGAINST RETINAL ANTIGENS ARE FREQUENTLY OBSERVED

In contrast, there is considerable evidence to suggest that glaucomatous degeneration is frequently accompanied by the presence of serum autoantibodies directed against retinal antigens.^{11–13} These have been observed in both primary and secondary glaucomas, including exfoliation glaucoma, suggesting that their appearance is not the primary cause of RGC death, but is most likely a consequence thereof. It seems that antibodies appear to be capable to exit the retinal vasculature and binding to targets within the RGC layer.¹⁴

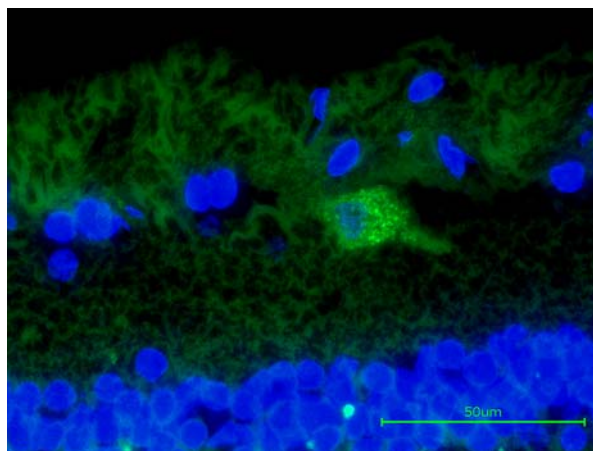


FIGURE 1. Immunohistochemical detection of endogenous IgG (green label) bound to retinal ganglion cells in the retina of a human eye donor with glaucoma. In the sagittal section IgG was detected following incubation with an anti-human IgG antibody. Nuclei were counterstained with DAPI (blue) to facilitate orientation. Image courtesy of Dr O. Gramlich (University of Mainz), reprinted with permission.

Received for publication July 28, 2014; accepted August 2, 2014.
From the Department of Ophthalmology and Visual Sciences, The University of Iowa, 200 Hawkins Drive, Iowa City, IA 52242.
Disclosure: The author declares no conflict of interest.
Reprints: Markus H. Kuehn, PhD, Department of Ophthalmology and Visual Sciences, The University of Iowa, 200 Hawkins Drive, Iowa City, IA 52242 (e-mail: markus-kuehn@uiowa.edu).
Copyright © 2014 by Lippincott Williams & Wilkins
DOI: 10.1097/IJG.0000000000000115

The presence of anti-RGC antibodies are potentially pathologic, and indeed injection of antibodies directed against heat shock proteins or preparations of optic nerve proteins into the tail veins of mice or rats have been reported to result in RGC loss.^{15,16} Although these data demonstrate that it is in principle possible for serum antibodies to cause RGC death, it must be cautioned that in these experiments antibodies were administered with Freud incomplete adjuvant or pertussis toxin, which might create an unphysiological degree of retinal vessel leakage or an excessively proinflammatory environment. Nevertheless, these experiments indicate that under the right circumstances, IgG accumulation in the retina can lead to RGC death. Binding of IgG to RGC can also be observed in the retinas of human eye donors.¹⁴ Immunohistochemical detection of human IgG in retinas of donors with or without glaucoma reveals that approximately 1% of all ganglion cells are bound by autoantibodies (Fig. 1). The fraction of antibody-bound RGC appears to be slightly higher in glaucomatous retina, but eyes from older donors without glaucoma also contain an appreciable number of such cells. The presence of IgG-bound RGC and the fact that the serum of older nonglaucomatous patients also contains antiretinal IgG raises the question: if autoantibodies are capable of inducing RGC damage, why does this not occur in nonglaucomatous individuals or in the second eye of a unilateral glaucoma case?

THE ROLE OF THE COMPLEMENT CASCADE IN NEUROINFLAMMATION

One explanation might be that effective mechanisms exist to avoid destruction of RGC through a retinal immune response. Cells bound by antibody are not necessarily condemned to cell death, particularly in an environment such as the retina without cytotoxic T cells, macrophages, or natural killer cells. However, one process that can quickly result in the degeneration of an antibody-bound cell in the retina is the activation of the classic complement cascade. This process, which is frequently initialized by immunoglobulins binding to the surface of a pathogen or a degenerating cell, can result in the formation of the membrane attack complex (MAC) and lead to cell lysis if left uninhibited. The degeneration of RGC in the retina secondary to, for example, IOP elevation is accompanied by the marked accumulation of components of the classic complement cascade, including complement component 1Q (C1Q) and complement component 3 (C3), in association with RGC and the formation of MAC.^{17,18} In human donor eyes with advanced glaucoma, MAC labeling can be regionally observed on the majority of RGCs, presumably associated with areas of active RGC degeneration (Fig. 2).

Studies using complement-deficient mice demonstrate that in animals lacking a functional complement cascade, RGC death occurs more slowly, although ultimately a similar number of RGC are lost.^{7,19,20} These findings suggest that the role of complement activation is to actively promote the rapid demise and clearance of damaged RGC cells. Such a mechanism might be desirable to avoid the development of an autoimmune response (reviewed in Alexander et al²¹). Patients with C1 and C2 deficiencies frequently develop autoimmune disease, and it has been hypothesized that this is the result of inefficient clearance of debris following cell death, thus allowing an opportunity for the immune system to mount a response.^{22,23} One could

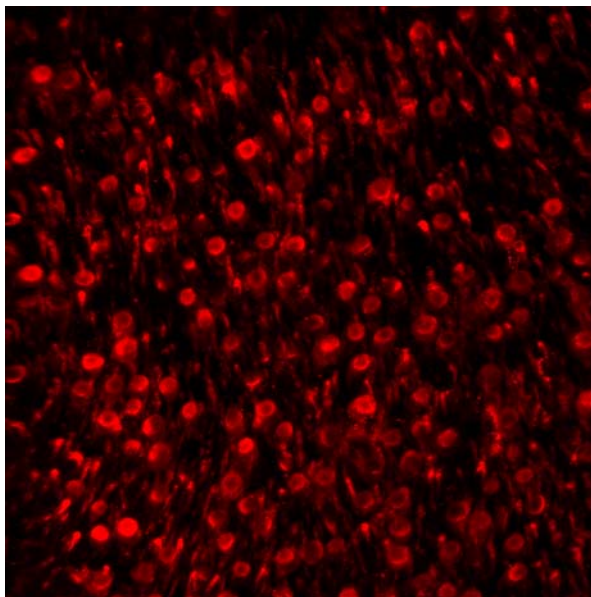


FIGURE 2. Immunohistochemical detection of MAC associated with retinal ganglion cells. In this image of a flat-mounted retina of a human donor with advanced glaucoma, profound labeling is observed in distinct regions. Other retinal regions of the same eye exhibit far fewer MAC-positive cells or none at all. MAC indicates membrane attack complex.

hypothesize that an autoimmune response in the retina might result either from the prolonged presence of degenerating RGCs or perhaps from a brief, but catastrophic, disruption of the blood-retina barrier as in the case of splinter hemorrhage.

LACK OF A PROINFLAMMATORY ENVIRONMENT COULD PROTECT THE HEALTHY EYE FROM AUTOIMMUNITY

Glaucoma-associated activation of complement in the retina is accompanied by synthesis of C1Q, C3, and, perhaps, C4 by retinal cells.¹⁷ Local synthesis of these initiating components not only avoids a systemic response of the innate immune system, but also allows a response that is attuned to the severity of the RGC damage. Importantly, C1Q synthesis is readily detectable in glaucomatous eyes but is very low or absent in healthy eyes. This local control over the magnitude of the complement response may explain why the presence of autoantibodies in patients without glaucoma does not lead to the development of RGC loss, or why damage to the contralateral eye in cases of unilateral glaucoma might be comparatively mild or even absent: if activation of complement and the formation of MAC serves to eliminate RGC bound by IgG, then the absence of C1Q synthesis in otherwise healthy eyes prevents initiation of this process. Consequently, the presence of anti-RGC antibodies in the serum might result in IgG-bound RGC in the second eye of unilateral glaucoma cases, but not in the destruction of these cells.

There are currently few data to support or refute this hypothesis. However, some predictions could be made:

- (1) Depending on the type of autoantibody created and the predisposition of the patient, significant differences may exist between individuals.
- (2) Effects on the contralateral eye will generally be mild, but progressive.
- (3) The establishment of a proinflammatory environment, even due to nonocular conditions, could significantly influence the extent to which autoimmune processes exert damage. Analogous to the events observed in the brain primed microglia and macroglia in the contralateral eye may become damaging in response to systemic inflammation.²⁴

Finally, studies testing the notion that the second eye in patients with unilateral glaucoma remains unaffected would contribute much to this question. Such studies might involve nerve fiber layer thickness measurements in the second eye over several years, using consistent instrumentation and parameters. Patients with moderate to advanced glaucoma may develop damage through mechanisms that are unaffected by modulating IOP. Consequently, an autoimmune component to glaucoma, if it indeed contributes to pathology in humans, would require treatment paradigms that are far different from current medical practice.

REFERENCES

1. Morrison JC, Moore CG, Deppmeier LM, et al. A rat model of chronic pressure-induced optic nerve damage. *Exp Eye Res.* 1997;64:85–96.
2. Moreno MC, Marcos HJ, Oscar Croxatto J, et al. A new experimental model of glaucoma in rats through intracameral injections of hyaluronic acid. *Exp Eye Res.* 2005;81:71–80.
3. Grozdanic SD, Kwon YH, Sakaguchi DS, et al. Functional evaluation of retina and optic nerve in the rat model of chronic ocular hypertension. *Exp Eye Res.* 2004;79:75–83.
4. Chen H, Wei X, Cho KS, et al. Optic neuropathy due to microbead-induced elevated intraocular pressure in the mouse. *Invest Ophthalmol Vis sci.* 2011;52:36–44.
5. Rasmussen CA, Kaufman PL. Primate glaucoma models. *J Glaucoma.* 2005;14:311–314.
6. Gallego BI, Salazar JJ, de Hoz R, et al. IOP induces upregulation of GFAP and MHC-II and microglia reactivity in mice retina contralateral to experimental glaucoma. *J Neuroinflammation.* 2012;9:92–110.
7. Kuehn MH, Kim CY, Jiang B, et al. Disruption of the complement cascade delays retinal ganglion cell death following retinal ischemia-reperfusion. *Exp Eye Res.* 2008;87:89–95.
8. Yucel YH, Zhang Q, Weinreb RN, et al. Effects of retinal ganglion cell loss on magno-, parvo-, koniocellular pathways in the lateral geniculate nucleus and visual cortex in glaucoma. *Prog Retin Eye Res.* 2003;22:465–481.
9. Yucel YH, Zhang Q, Weinreb RN, et al. Atrophy of relay neurons in magno- and parvocellular layers in the lateral geniculate nucleus in experimental glaucoma. *Invest Ophthalmol Vis sci.* 2001;42:3216–3222.
10. Gupta N, Greenberg G, de Tilly LN, et al. Atrophy of the lateral geniculate nucleus in human glaucoma detected by magnetic resonance imaging. *Br J Ophthalmol.* 2009;93:56–60.
11. Altintas O, Yuksel N, Sonmez GT, et al. Serum antiphospholipid antibody levels in pseudoexfoliation. *J Glaucoma.* 2012;21:326–330.
12. Dervan EW, Chen H, Ho SL, et al. Protein microarray profiling of serum autoantibodies in pseudoexfoliation glaucoma. *Invest Ophthalmol Vis sci.* 2010;51:2968–2975.
13. Joachim SC, Bruns K, Lackner KJ, et al. Analysis of IgG antibody patterns against retinal antigens and antibodies to alpha-crystallin, GFAP, and alpha-enolase in sera of patients with “wet” age-related macular degeneration. *Graefes Arch Clin Exp Ophthalmol.* 2007;245:619–626.
14. Gramlich OW, Beck S, von Thun Und Hohenstein-Blaul N, et al. Enhanced insight into the autoimmune component of glaucoma: IgG autoantibody accumulation and pro-inflammatory conditions in human glaucomatous retina. *PLoS One.* 2013;8:e57557.
15. Wax MB, Tezel G, Yang J, et al. Induced autoimmunity to heat shock proteins elicits glaucomatous loss of retinal ganglion cell neurons via activated T-cell-derived fas-ligand. *J Neuroscience.* 2008;28:12085–12096.
16. Laspas P, Gramlich OW, Muller HD, et al. Autoreactive antibodies and loss of retinal ganglion cells in rats induced by immunization with ocular antigens. *Invest Ophthalmol Vis sci.* 2011;52:8835–8848.
17. Kuehn MH, Kim CY, Ostojic J, et al. Retinal synthesis and deposition of complement components induced by ocular hypertension. *Exp Eye Res.* 2006;83:620–628.
18. Stasi K, Nagel D, Yang X, et al. Complement component 1Q (C1Q) upregulation in retina of murine, primate, and human glaucomatous eyes. *Invest Ophthalmol Vis sci.* 2006;47:1024–1029.
19. Howell GR, Macalino DG, Sousa GL, et al. Molecular clustering identifies complement and endothelin induction as early events in a mouse model of glaucoma. *J Clin Invest.* 2011;121:1429–1444.
20. Howell GR, Soto I, Ryan M, et al. Deficiency of complement component 5 ameliorates glaucoma in DBA/2J mice. *J Neuroinflammation.* 2013;10:76.
21. Alexander JJ, Anderson AJ, Barnum SR, et al. The complement cascade: Yin-Yang in neuroinflammation—neuro-protection and -degeneration. *J Neurochem.* 2008;107:1169–1187.
22. Truedsson L, Bengtsson AA, Sturfelt G. Complement deficiencies and systemic lupus erythematosus. *Autoimmunity.* 2007;40:560–566.
23. Fraser DA, Tenner AJ. Directing an appropriate immune response: the role of defense collagens and other soluble pattern recognition molecules. *Curr Drug Targets.* 2008;9:113–122.
24. Perry VH. Contribution of systemic inflammation to chronic neurodegeneration. *Acta Neuropathologica.* 2010;120:277–286.